

LETTER

Ototoxicity Associated with Oxaliplatin in a Patient with Pancreatic Cancer

Sun Young Oh¹, Nawal Wasif², Marie Carmel Garcon³,
Gladys Rodriguez³, Muhammad Wasif Saif¹

¹Department of Hematology/Oncology and Experimental Therapeutics, Tufts University School of Medicine. Boston, MA, USA. ²Brookline High School. Brookline, MA, USA. ³Columbia University Medical Center. New York, NY, USA

Summary

Context Oxaliplatin, a third-generation platinum derivative is commonly used for the treatment of colorectal cancer, pancreatic cancer, upper gastrointestinal cancer, hepatobiliary cancer, and ovarian cancer. Neurotoxicity is the dose limiting toxicity and ototoxicity is very rare, less than 1% of patients. **Case report** We present a case of a female patient with locally advanced unresectable pancreatic cancer who developed hearing loss after receiving oxaliplatin and gemcitabine. The dose of oxaliplatin was reduced but continued due to clinical benefit and radiological response. **Discussion** To the best of our knowledge, this is the third case report of oxaliplatin-induced ototoxicity. Ototoxicity seems to be a rare complication of oxaliplatin therapy. Regardless of its rare occurrence, clinicians should be aware of this severe complication and be diligent in monitoring patients' clinical symptoms.

Introduction

Oxaliplatin is a third-generation diamine cyclohexane platinum derivative which mechanism of action involves the formation of DNA adducts and inhibition of the DNA synthesis [1]. The clinical development of oxaliplatin-based chemotherapy regimens started in the 1990s and along the years, several different combination regimens have been used in oncology [2]. Oxaliplatin is widely used for the treatment of various solid organ malignancies including colorectal cancer, pancreatic cancer, upper gastrointestinal cancer, hepatobiliary cancer, and ovarian cancer. In pancreatic cancer, oxaliplatin is used in combination with 5-fluorouracil, leucovorin and irinotecan (FOLFIRINOX) for patients with metastatic disease [3].

While neurotoxicity is a frequently reported side-effect of oxaliplatin (76%) [1], it displays a characteristic pattern; an acute onset neuropathy

which may occur immediately after infusion, characterized by cold-exacerbated paresthesia, muscle spasm and fasciculation. These acute symptoms typically resolve within a week, but, at higher cumulative doses, oxaliplatin induces dose-limiting sensory neuropathy and leads to persistent functional impairment and even ataxia [2]. Among patients who received oxaliplatin for duration of 5-7 months, such neurotoxic adverse reaction occurs approximately in 50% [2]. Other major oxaliplatin related side effects include fatigue, diarrhea, nausea, vomiting, stomatitis and abdominal pain [1].

Ototoxicity related to the use of platinum derivatives, especially cisplatin has been well documented. However, development of ototoxicity after use of oxaliplatin is very rare, less than 1% of patients. Here we present a case of a female patient who developed hearing loss after receiving oxaliplatin and gemcitabine (Gem-Ox) for locally advanced, unresectable pancreatic cancer.

Case report

An 85-year-old Caucasian woman presented initially with a 3-month history of decreased appetite, nausea, vomiting, weight loss, and fatigue. Her past medical history was significant for hypertension, diabetes mellitus, presbycusis, cataract, and glaucoma. She had an ultrasound of

Received June 5th, 2013 – Accepted August 2nd, 2013

Key words Deafness; Hearing Loss; oxaliplatin; Pancreatic Neoplasms; Peripheral Nervous System Diseases

Correspondence Muhammad Wasif Saif

Section of GI Cancers and Experimental Therapeutics; Tufts University School of Medicine; 800 Washington Street; Boston, MA 02111; USA

Phone: +1-617.636.5627; Fax: +1-617.636.8535

E-mail: wsaif@tuftsmedicalcenter.org

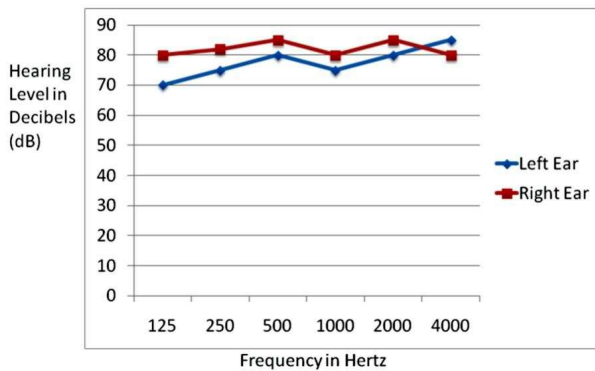


Figure 1. Post-oxaliplatin audiogram.

the abdomen and it revealed a 2.8 cm mass at the head of pancreas. A CT scan of abdomen and pelvis showed 2.9 cm mass at the head of pancreas as well as pancreatic ductal dilatation, and the tumor was found to encompass approximately 50% of the celiac axis and 50% of the superior mesenteric vein. The biopsy confirmed adenocarcinoma. Because of her locally advanced unresectable pancreatic cancer, neoadjuvant chemotherapy was initiated with oxaliplatin (85 mg/m²) and gemcitabine (1,000 mg/m²) given at day 1 which was repeated every 14 days (same day oxaliplatin and gemcitabine) [4, 5]. The patient had a history of moderate to severe bilateral presbycusis necessitating her to wear and use a hearing aid for more than 32 years.

At the end of third cycle (cumulative dose: 85 x 3 = 255 mg/m²), the patient noticed further difficulty in hearing. An audiogram was obtained as shown below in Figure 1.

The audiogram showed that the speech recognition threshold was decreased from 55 dB to 85 dB when compared to baseline audiogram (Figure 2).

This change confirmed her to progress from moderate to profound hearing loss as depicted in Table 1. The patient denied vertigo, tinnitus, or any other cranial nerve symptoms.

Her pancreatic tumor clearly responded to same day oxaliplatin and gemcitabine by CT scan, which showed 15.6% decrease in size after fourth cycle. Also her CA 19-9 level was reduced by 60%. Therefore her treatment was continued with dose reduction of oxaliplatin from 85 mg/m² to 65

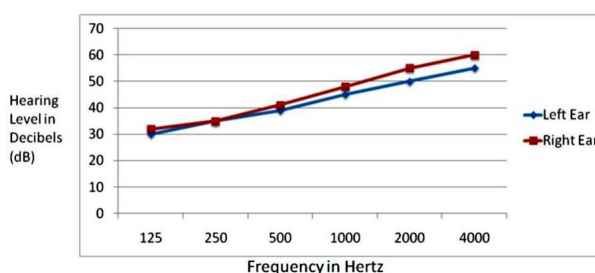


Figure 2. Pre-oxaliplatin audiogram.

Table 1. The following table relates how loud a sound must be for a person to hear it (hearing thresholds) to the degree of hearing loss for adults.

Severity	Average Symptoms loss
Mild	20-40 dB • Difficulty with soft speech • Sustained attention sometimes difficult
Moderate	41-55 dB • Difficulty with normal conversational speech • Moderate difficulty in group or noisy situations
Moderately-severe	56-70 dB • Hears shouted speech only • Appears to not pay attention
Severe	71-90 dB • Hears only amplified speech (with hearing aid or personal amplifier) • May distinguish vowel sounds but not consonant sounds
Profound	91+ dB • Difficulty hearing even with amplification • Speech and language are distorted

mg/m² starting from fourth cycle. We added calcium and magnesium salts pre- and post-oxaliplatin infusion [6, 7]. Her hearing aid was upgraded.

The patient completed a total of 10 cycles of same day oxaliplatin and gemcitabine with cumulative dose of 710 mg/m² (85 x 3 = 255 mg/m² plus 65 x 7 = 455 mg/m²), followed by one-month duration of chemoradiation therapy with capecitabine. Repeat imaging was obtained after completion of chemoradiation therapy and it showed further decrease in size of the tumor from 2.9 cm initially to 1.4 cm. Given the potential need for an arterial reconstruction in case of a surgery, the patient was not considered to be a surgical candidate and her chemotherapeutic regimen was changed to single agent therapy with gemcitabine. Her further clinical course was complicated by severe neutropenia leading to interruptions in therapy and subsequent dose reduction. However, her hearing remained unchanged. Follow-up CT scans revealed stable disease status and improvement in vascular involvement of the tumor.

Discussion

Platinum-based chemotherapeutic agents are widely used in various malignancies including pancreatic cancer [8]. However, like other chemotherapeutic agents, they have significant adverse effects that commonly limit their therapeutic use. Oxaliplatin is a third generation cisplatin analog and it is considered to be far less nephrotoxic and ototoxic compared to cisplatin or carboplatin [2].

The main targets of the platinum derivative-related ototoxicity are the outer hair cells in the organ of

Table 2. Comparison of three cases with ototoxicity following oxaliplatin.

Reference	Age/Sex	Diagnosis	Regimen	Cumulative dose when ototoxicity developed	Management
Malhotra <i>et al.</i> [11]	70/Female	Stage III adenocarcinoma of rectum	Capecitabine and oxaliplatin	85 mg/m ²	Stopped after 1 st dose
Vietor and George [12]	46/Female	Stage IIIC adenocarcinoma of sigmoid colon	mFOLFOX-6	170 mg/m ²	Cycle 3 was held and reintroduced at reduced dosage from 50% which was increased to 75% from cycle 6 through 12
Present case	85/Female	Locally advanced unresectable pancreatic cancer	Gemcitabine and oxaliplatin	255 mg/m ²	Dose reduction by 25% from cycle 4 and completed total of 10 cycles

mFOLFOX-6: modified 5-fluorouracil, leucovorin and oxaliplatin (FOLFOX) 6: leucovorin 350 mg/m² i.v. over 2 hours before 5-fluorouracil, day1 5-fluorouracil 400 mg/m² i.v. bolus day 1 followed by 2,400 mg/m² i.v. over 46 hours oxaliplatin 85 mg/m² i.v. day 1

Corti and the vascularized epithelium in the lateral wall of the cochlea, the *stria vascularis* [9]. The organ of Corti is protected by a blood-labyrinth barrier that restricts the entry of platinum derivatives to the perilymphatic compartment of the inner ear. Disruption of this blood-labyrinth barrier by a loop diuretic or noise exposure enhances the entry of the drug to the inner ear perilymphatic compartment and can potentiate the amount of damage [10]. Among three platinum derivatives in clinical use, cisplatin is considered as the most ototoxic agent. It was proposed that the major difference in the ototoxic profile of various platinum compounds might arise from several different metal transporters that selectively regulate the influx, efflux and sequestration of these drugs [10]. In this regard, recent pharmacokinetic studies have revealed that the cochlear uptake of oxaliplatin is considerably less than the uptake of cisplatin that may explain their different ototoxic profiles [9].

To the best of our knowledge, this is the third case report of oxaliplatin-induced ototoxicity as shown in Table 2 [11, 12]. Previously, Malhotra *et al.* have reported a case of acute unilateral ototoxicity following a single intravenous infusion of oxaliplatin that was minimally improved after 2 years of follow-up [11]. Vietor and George have described a case of oxaliplatin-induced ototoxicity and transient hepatotoxicity [12].

Ototoxicity seems to be a rare complication of oxaliplatin therapy. Therefore, it is difficult to generalize the guidance in regard to the prediction of the ototoxic side effect from this drug. Our patient and the patient in the report by Vietor and George [12] were not taking known ototoxic medication including loop diuretics. All three subjects in reported cases are female and it appears that the ototoxicity occurs at lower cumulative dosage compare to neuropathy which occurs in 10-15% of patients after a cumulative dose of 780 to 850 mg/m² [13]. Regardless of its rare occurrence, clinicians should be aware of this severe complication and be diligent in monitoring patients'

clinical symptoms. We suggest in patients with known risk factors for hearing problems, prior exposure to ototoxic drugs, or planned treatment at high doses, hearing monitoring should be considered. Further research to define the potential for ototoxicity using this chemotherapy is warranted.

Conflict of interest The authors have no potential conflict of interest

References

- Ibrahim A, Hirschfeld S, Cohen MH, Griebel DJ, Williams GA, Pazdur R. FDA drug approval summaries: oxaliplatin. *Oncologist*. 2004;9(1):8-12.
- Hoff PM, Saad ED, Costa F, Coutinho AK, Caponero R, Prolla G, Gansl RC. Literature review and practical aspects on the management of oxaliplatin-associated toxicity *Clin Colorectal Cancer*. 2012 Jun;11(2):93-100
- Conroy T, Desseigne F, Ychou M, Bouché O, Guimbaud R, Bécouarn Y, Adenis A, Raoul JL, Gourgou-Bourgade S, de la Fouchardière C, Bennouna J, Bachtet JB, Khemissa-Akouz F, Péré-Vergé D, Delbaldo C, Assenat E, Chauffert B, Michel P, Montoto-Grillot C, Ducreux M; Groupe Tumeurs Digestives of Unicancer; PRODIGE Intergroup. FOLFIRINOX versus gemcitabine for metastatic pancreatic cancer. *N Engl J Med*. 2011 May 12;364(19):1817-25
- Li J, Merl M, Lee MX, Kaley K, Saif MW. Safety and efficacy of single-day GemOx regimen in patients with pancreatobiliary cancer: a single institution experience. *Expert Opin Drug Saf*. 2010 Mar;9(2):207-13.
- Afchain P, Chibaudel B, Lledo G, Selle F, Bengrine-Lefevre L, Nguyen S, Paitel JF, Mineur L, Artru P, André T, Louvet C. First-line simplified GEMOX (S-GemOx) versus classical GEMOX in metastatic pancreatic cancer (MPA): results of a GERCOR randomized phase II study. *Bull Cancer*. 2009 May;96(5):E18-22.
- Saif MW, Reardon J. Management of oxaliplatin-induced peripheral neuropathy. *Ther Clin Risk Manag*. 2005 Dec;1(4):249-58.
- Saif MW. Oral Calcium Ameliorating Oxaliplatin-Induced Peripheral Neuropathy. *J Appl Res*. 2004 Jan 1;4(4):576-582.
- Saif MW, Kim R. Role of platinum agents in the management of advanced pancreatic cancer. *Expert Opin Pharmacother*. 2007 Nov;8(16):2719-27.
- Hellberg V, Wallin I, Eriksson S, Hernlund E, Jerremalm E, Berndtsson M, Eksborg S, Arnér ES, Shoshan M, Ehrsson H, Laurell G. Cisplatin and oxaliplatin toxicity: importance of cochlear kinetics as a determinant for ototoxicity. *J Natl Cancer Inst*. 2009 Jan 7;101(1):37-47

10. Ding D, Allman BL, Salvi R. Review: ototoxic characteristics of platinum antitumor drugs . *Anat Rec (Hoboken)*. 2012 Nov;295(11):1851-67

11. Malhotra NK, Aslam R, Lipman SP, Bilski VJ. Acute ototoxicity from a single infusion of oxaliplatin. *Ear Nose Throat J*. 2010 Jun;89(6):258-61

12. Vietor NO, George BJ. Oxaliplatin-induced hepatocellular injury and ototoxicity: a review of the literature and report of unusual side effects of a commonly used chemotherapeutic agent. *J Oncol Pharm Pract*. 2012 Sep;18(3):355-9.

13. Cassidy J, Misset JL. Oxaliplatin-related side effects: characteristics and management. *Semin Oncol*. 2002 Oct;29(5 Suppl 15):11-20.
