

CASE REPORT

Reconstructive Strategy after Pancreaticoduodenectomy in Partially Gastrectomized Patients

Paolo Bechi, Lorenzo Dioscoridi

Department of Surgery and Translational Medicine, University of Florence. Florence, Italy

ABSTRACT

Context Pancreaticoduodenectomy in partially-gastrectomized patients presents some peculiarities of the reconstructive phase. Above all, in B II and Roux-en-Y partial gastrectomies, a gastric re-resection with a redo gastrojejunal anastomosis should be avoided because it is often needlessly time-consuming and risky. In our series of 7 consecutive patients, either one of two reconstruction methods was used, depending upon the length of the pre-existing afferent loop. **Case reports** In order to better illustrate this strategy, two cases of carcinoma of the duodenal papilla are reported. Both of the patients had previously undergone partial gastrectomy with B II reconstruction for peptic ulcers. Both were admitted to our hospital with a past history of jaundice. However, whereas in Case #2 a sufficiently long pre-existent afferent loop could be utilized for the pancreatic and bile duct anastomoses, in Case #1 a shorter afferent loop was removed and the efferent loop was utilized for the anastomoses. The postoperative course was uneventful in both patients. **Conclusions** This reconstructive strategy for pancreaticoduodenectomy in gastrectomized patients, which uses either of the methods described above, has produced good results in our series of 7 patients and appears to be rational and straightforward.

INTRODUCTION

One of the steps of pancreaticoduodenectomy (PD) is represented by partial gastrectomy (PG). Therefore, when partially-gastrectomized patients need a PD, the step of a second PG with gastrojejunostomy (Figure 1) should be omitted, whenever possible, in order to simplify the procedure and prevent morbidity/mortality [1, 2]. This applies to PG with either B II or Roux-en-Y (the post-PD reconstructive strategy is exactly the same for both reconstructions), but not for B I, which inevitably requires a re-resection with a new gastrojejunostomy. A number of re-resection sparing methods have been proposed with no standardization of the respective indications [3, 4]. Moreover, all papers concerning the reconstructive phase of PD in gastrectomized patients deal with small series, the most extensive one consisting of eight patients [2]. Although our series consists of solely seven patients, we propose standardization and systematization of the reconstruction methods. For a better understanding of this paper and of the strategy recommended, two cases are reported.

CASE REPORTS

Case #1

A seventy-five-year-old woman with a neoplasm of the duodenal papilla (adenocarcinoma at the histopathologic examination of the endoscopic biopsies) was admitted to our hospital. Jaundice had completely disappeared following a biliary stenting performed two months earlier in another hospital. A partial gastrectomy with B II reconstruction for gastric ulcer emerged from her history. After a CT scan that did not show any vascular involvement and only peripancreatic nodal involvement, a PD was scheduled. During the operation, in a transmesocolic B II, the gastrojejunal anastomosis appeared very close to the duodenojejunal flexure and the afferent loop was quite short (Figure 2, upper left panel). Therefore, the afferent loop was stapled immediately upstream of the gastric remnant for its complete removal within the specimen. The reconstructive phase consisted of stapling the efferent jejunal loop 40 cm downstream of the gastric remnant and utilizing its distal end for the pancreatic and the bile duct anastomoses. For this purpose, the distal arm of the divided jejunum was brought up through the mesocolon and an end-to-end invaginating telescope-type pancreaticojejunal anastomosis was performed. A termino-lateral hepaticojejunal anastomosis was also performed with a 4-0 monolayer absorbable suture 20 cm from the first anastomosis (Figure 2, upper right panel).

Finally, a latero-lateral jejunal anastomosis was performed between the proximal end of the efferent limb of the previous gastrojejunal anastomosis and the brought up jejunal loop 30 cm from the hepaticojejunal anastomosis. The histopatologic exam of the operative specimen confirmed a pT3 N2b, well-differentiated adenocarcinoma

Received November 20th, 2014 – **Accepted** February 20th, 2015

Keywords Pancreaticoduodenectomy; Gastrectomy; Anastomosis, Surgical

Correspondence Lorenzo Dioscoridi
Department of Surgery and Translational Medicine
Largo Brambilla 3
50138 Florence, Italy
Phone: +39-333.495.0733
Fax: +39-055.794.7399
E-mail: dioscoridi.lorenzo@virgilio.it

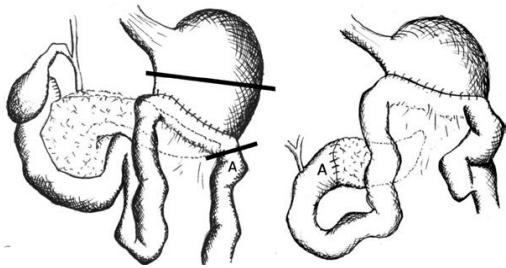


Figure 1. Gastric re-resection in pancreaticoduodenectomy in a patient with a B II partial gastrectomy. The demolitive (left panel) and the reconstructive (right panel) phases are represented, respectively. This procedure should be avoided in B II and Roux-en-Y partial gastrectomies, whereas it represents a forced option in B I partial gastrectomy.

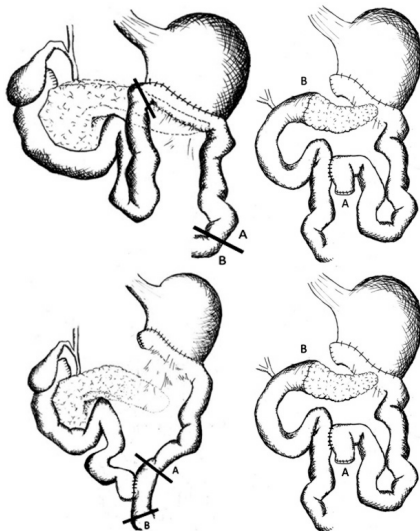


Figure 2. The demolitive (upper left panel) and the reconstructive (upper right panel) phases of pancreaticoduodenectomy when a short afferent loop is present in a previous B II partial gastrectomy. The afferent loop is stapled and removed within the specimen, whereas the efferent loop is stapled (upper left panel) and its distal end utilized for the pancreatic and bile duct anastomoses (upper right panel). This procedure has been followed in Case #1. The demolitive (lower left panel) and reconstructive (lower right panel) phases follow the above described steps also when a short afferent loop to the jejuno-jejunal anastomosis is present in a Roux-en-Y partial gastrectomy.

of the duodenal papilla. After an uneventful postoperative course, the patient went home on the 10th postoperative day and, 6 months later, she is doing well, although still undergoing adjuvant chemotherapy.

Case #2

A fifty-nine-year-old woman with an adenocarcinoma of the duodenal papilla was referred to our hospital due to a progressive obstructive jaundice. Her history included a PG for a duodenal ulcer.

At laparotomy, a B II PG was evidenced with a long afferent loop to an antecolic gastrojejunal anastomosis which was located 50-60 cm downstream of the ligament of Treitz. The length of the afferent loop enabled to remove the proximal 10 cm of jejunum with the specimen and to use the remaining 50 cm for the pancreatic and bile duct anastomoses (Figure 3, upper left panel). Therefore, the afferent loop of the gastrojejunostomy was stapled a few centimeters downstream of the duodenojejunal flexure and its distal end was brought up and anastomosed exactly

as previously described for Case #1 (Figure 3, upper right panel). No additional anastomosis was needed. Therefore, an anastomosis and operative time were spared in comparison with the reconstructive method of the Case #1. The histopathologic exam on the operative specimen confirmed a T2 N0 well-differentiated adenocarcinoma of the papilla.

After an uneventful postoperative course, the patient went home on the 16th postoperative day and she was fine up to two years later, when she was lost from follow-up.

DISCUSSION

The strategy to be followed in the reconstructive phase of PD in gastrectomized patients has not been defined previously because of the wide variety of reconstructions, which have been proposed mostly in small series [2, 5].

This paper centers exclusively on PD after PG, although the strategy which is proposed for the reconstruction seems suitable for total gastrectomy as well. Moreover, no issues exist for the quite unusual B I reconstruction after PG, in which a gastric re-resection with a new gastrojejunal anastomosis is unavoidable. In contrast, in both in B II and Roux-en-Y reconstructions a re-resection can be avoided in order to decrease surgical time and risks of complications. Above all, a new gastrojejunal anastomosis, as opposed to a well-functioning long-standing one, might imply, in the postoperative course, a greater stasis of both bile and pancreatic juice in the afferent loop with greater risk of pancreatic fistula [6].

When re-resection is excluded (as it should be), the main conditioning factor for reconstruction is represented by the length of the jejunum from the duodenojejunal flexure to the gastrojejunal (in B II) or the jejuno-jejunal (in Roux-en-Y) anastomosis. An afferent loop length of 50 cm will allow its utilization for the pancreatic and biliary anastomoses with an adequate distance between each of the final three anastomoses (see Case #2). On the contrary, a shorter afferent loop requires its excision within the specimen and the utilization of the efferent loop for reconstruction in a Roux-en-Y fashion (see Case #1). Indeed, an insufficient distance between the anastomoses could cause a pancreatic fistula [6, 7, 8] and/or recurrent cholangitis [5, 9]. Reconstruction as in Case #1 implies an additional jejuno-jejunal anastomosis when compared to Case #2 and for this reason a shorter afferent loop appears to be less favourable, although it is more common.

Some alternatives to these reconstructions have been proposed, but all appear to be technically and/or conceptually much more complex [1, 3, 4]. Therefore, whereas re-resection may exceptionally represent an unavoidable choice also in B II or Roux-en-Y gastrectomies for vascular or oncologic reasons, solutions like the interposition of a pedicled jejunal conduit (3) or preservation of both the afferent and efferent loop to both be anastomosed to the jejunal pull-up [4] seem even more complex than re-resection itself.

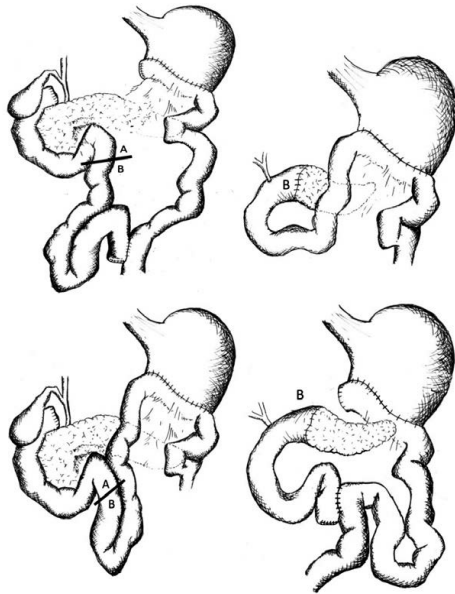


Figure 3. The demolitive (upper left panel) and the reconstructive (upper right panel) phases of pancreaticoduodenectomy when a sufficiently long afferent loop is present in a previous B II partial gastrectomy. In spite the afferent loop is stapled downstream the duodenojejunal flexure (upper left panel), the length of the distal end of the afferent loop allows its utilization for the pancreatic and biliary anastomoses with an adequate distance between each of the final three anastomoses (upper right panel). This procedure has been followed in Case #2. The demolitive (lower left panel) and reconstructive (lower right panel) phases follow the above described steps also when a sufficiently long afferent loop to the jejuno-jejunal anastomosis is present in a Roux-en-Y partial gastrectomy.

The approach proposed in this paper appears straightforward, although it could hardly be supported by evidence-based findings, since PD in PG is quite uncommon. Moreover, the previously reported series are no more extensive than ours and numerically adequate randomized prospective trials on this subject do not exist and can hardly be imagined. In addition to the good results obtained in these cases and in 5 others of our series, pathophysiological and clinical evidences seem to support this approach, in the perspective of taking advantage of what, at first glance, could appear to be an unfavourable condition: a pre-existing PG.

CONCLUSION

In this paper does not suggest any new procedure and each of the two proposed types of reconstruction are well known by pancreatic surgeons. However, it may help to identify a standardized reconstructive strategy for PD in PG.

Conflict of Interest

Authors declare to have no conflict of interest

References

1. Masi C, Bechi P, Fazi M, Pagliai P, Tanzi S. Le metodiche ricostruttive dopo duodenopancreatemia cefalica nei soggetti già operati di resezione gastroduodenale. *Giornale Italiano di Chirurgia* 1981; 37: 93-104.
2. Doi R, Fujimoto K, Imamura M. Effects of preceding gastrectomy on the outcome of pancreatoduodenectomy. *J Gastrointestinal Surg* 2004; 8: 575-579. [PMID: 15239994]
3. Howard JM. Pancreaticoduodenectomy: forty-one consecutive Whipple resections without an operative mortality. *Ann Surg* 1968; 168: 629-40. [PMID: 5680953]
4. Patel J, Patel JC, Leger L. Chirurgie du pancreas. Duodeno-pancreatectomie après intervention gastrique. *Nouveau traité de technique chirurgicale* 1969; 12: 559.
5. Yokoyama S, Sekioka A, Ueno K, Higashide Y, Okishio Y, Kawaguchi N et al. Pancreaticoduodenectomy following total gastrectomy: a case report and literature review. *World J Gastroenterol*. 2014; 20: 2721-2724. [PMID: 24627609]
6. Kingsnorth AN. Safety and function of isolated Roux loop duct-to-mucosa pancreaticojejunostomy after Whipple's pancreaticoduodenectomy. *Ann R Coll Surg Engl* 1994; 76: 175-179. [PMID: 7912489]
7. Sutton CD, Garcea G, White SA, O' Leary E, Marshall LJ, Berry DP et al. Isolated Roux-loop pancreaticojejunostomy: a series of 61 patients with zero postoperative pancreaticoenteric leaks. *J Gastrointestinal Surg* 2004; 8: 701-705. [PMID: 15358331]
8. Machado NO. Pancreatic fistula after pancreatectomy: definitions, risk factors, preventive measures, and management. *Review. Intern J Surg Oncol* 2012; [PMID: 22611494]
9. Kotoura Y, Takahashi T, Ishikawa Y, Ashida H, Hashimoto N, Nishioka A et al. Hepatobiliary and gastrointestinal imaging after pancreaticoduodenectomy- a comparative study on Billroth I and Billroth II reconstructions. *Jap J Surg* 1990; 20: 294-299. [PMID: 2359205]