

CASE REPORT

Laparoscopic Pancreas-Sparing Subtotal Duodenectomy

Ignasi Poves¹, Fernando Burdio¹, Sandra Alonso¹, Agustín Seoane², Luís Grande¹

Departments of ¹General and Digestive Surgery and ²Gastroenterology,
“Hospital del Mar”. Barcelona, Spain

ABSTRACT

Context Primary adenocarcinoma of the duodenum is a rare digestive malignancy which is commonly treated by radical surgical resection, pancreaticoduodenectomy being the technique of choice. Complete tumor resection obtaining free margins should be the standard of treatment for primary adenocarcinoma of the duodenum. Segmental duodenal resection is an appropriate operation for selected cases of primary adenocarcinoma of the duodenum of the 3rd and 4th portions of the duodenum. **Case report** We present the case of a 67-year-old woman suffering from an infra-ampullary large villous polypoid mass affecting the 3rd portion of the duodenum. Multiple endoscopic biopsies did not disclose any malignancy, and abdominal CT and endoscopic ultrasound found no extraduodenal involvement. A 3rd and 4th portion pancreas-sparing duodenectomy was carried out using a totally laparoscopic approach. Intra-operative duodenoscopy was done to safeguard the papilla of Vater. Recovery was uneventful and the patient was discharged on the 7th postoperative day. The final diagnosis was primary adenocarcinoma of the duodenum (free resection margins). After forty-five months of follow-up, the patient is free of disease. **Conclusions** We recommend this procedure for treatment of an infra-ampullary benign and pre-malignant duodenal pathology; it can also be a treatment option and an alternative to a pancreaticoduodenectomy in very selected cases of tumors confined to the duodenum. Expertise in both pancreatic surgery and laparoscopic techniques is required.

INTRODUCTION

Primary adenocarcinoma of the duodenum is a rare digestive malignancy. Radical surgical resection is considered the treatment of choice, and a pancreaticoduodenectomy is the preferred surgical procedure regardless of the tumor site which is usually periaampullary [1, 2]. Other more limited resection procedures, such as segmental duodenal resection and transduodenal excision, are considered only for selected cases [3, 4, 5, 6, 7]. Endoscopic snare excision and pancreas-sparing total duodenectomy have been considered only for the treatment of isolated benign polyps or in association with familial adenomatous polyposis [8]. The laparoscopic approach for resection of the duodenum is still experimental, having only been used in benign disease [9].

CASE REPORT

A 67-year-old woman with a body mass index of 40 Kg/m² was admitted to our hospital complaining of

acute upper gastrointestinal bleeding. She had experienced a syncope episode followed by melenas. An upper digestive endoscopy revealed a large friable polypoid mass about 5 cm in diameter, surrounding 3/4 of the internal lumen, coming from the 3rd portion of the duodenum, about 3 cm distal to the ampulla (Figure 1). There were no other polypoid lesions in the duodenum. Multiple endoscopic biopsies (five samples) confirmed a villous adenomatous polyp with mild-moderate dysplasia. Abdominal CT showed the mass to be confined to the duodenum. An extension

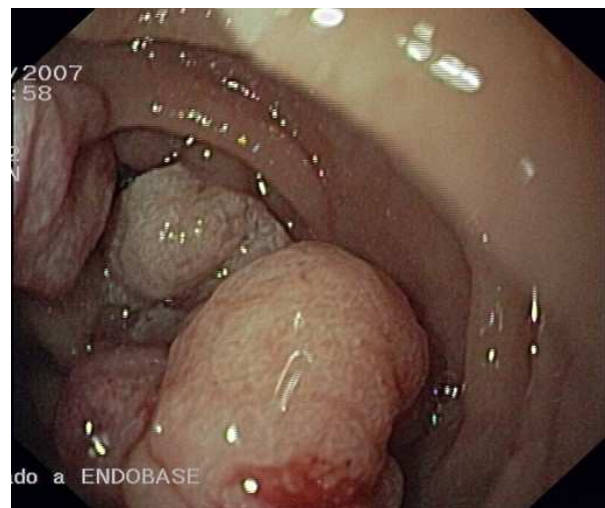


Figure 1. Duodenoscopy revealing a large polypoid mass.

Received September 16th, 2010 - Accepted December 14th, 2010

Key words Duodenal Neoplasms; Duodenoscopy; Laparoscopy /surgery; Pancreaticoduodenectomy

Correspondence Ignasi Poves

Hospital Universitari del Mar; Unit of Hepato-Biliary-Pancreatic Surgery; Department of General and Digestive Surgery; Passeig Marítim 25-29; 08003 Barcelona; Spain

Phone: +34-932.483.207; Fax: +34.932.483.433

E-mail: ipoves@parcdesalutmar.cat

URL <http://www.serena.unina.it/index.php/jop/article/view/3388/3668>

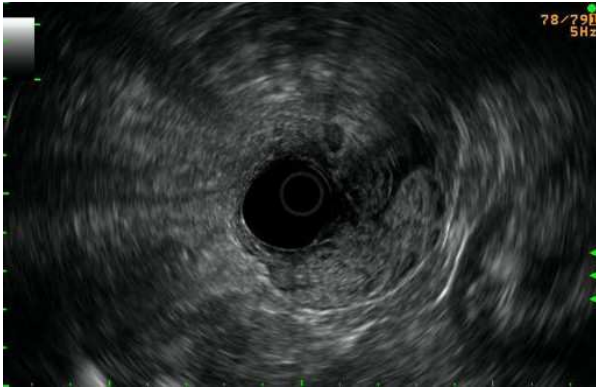


Figure 2. Endoscopic ultrasonography revealing the depth of invasion of the tumor into the muscular layers. The serosa was respected.

study was completed via endoscopic ultrasonography which showed no disruption of any of the muscle layers of the duodenum (Figure 2) and no penetration into the pancreas. The pancreatic duct was preserved and there were no pathological regional lymph nodes. Tumor markers (CEA and CA 19-9) were negative. From the day of admission to the day of the surgery, the patient required transfusion of 7 units of red blood cells.

A totally laparoscopic approach was used for the entire procedure using a five-port technique (Figure 3). The patient was placed in a reverse Trendelenburg position with the legs spread open. The surgeon stood between the patient's legs and the 2 assistants at each side of the surgeon. The surgical procedure was started with a complete Kocher's maneuver, detaching the greater omentum from the transverse colon along the avascular plane to the hepatic flexure of the colon. The head of the pancreas and the plane of the mesocolon were exposed. The tumor was clearly identified occupying the 3rd portion of the duodenum but having its origin near the 2nd portion. The retroduodenal and peripancreatic areas were carefully explored and no macroscopically pathological lymph nodes were found. Following dissection of the Treitz ligament, the first jejunal limb just distal to the duodenojejunal ligament was sectioned using a 45 mm linear cutter and 2.5 mm

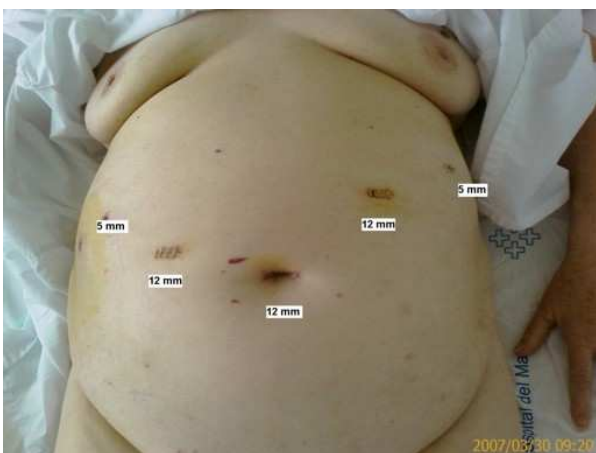

Figure 3. Placement of the five ports. Umbilical optic view.

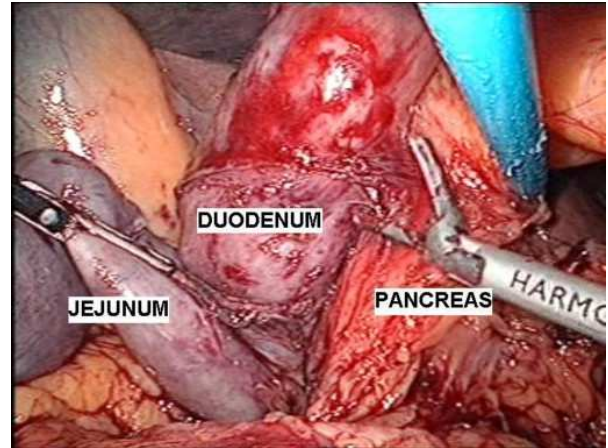


Figure 4. 3rd and 4th portions of the duodenum are spared from the head of the pancreas.

stapler. The sectioned proximal jejunum was then passed behind the mesenteric vessels. The duodenum was spared to the pancreas using ultrasound shears (Harmonic Ace™ 5 mm, Ethicon Endo-Surgery, Guaynabo, Puerto Rico) (Figure 4). By means of concomitant intraoperative duodenoscopic vision of the ampulla, the duodenum was sectioned, just infra-ampullary, above the tumor, obtaining adequate free margins (Figure 5). The intestinal tract was

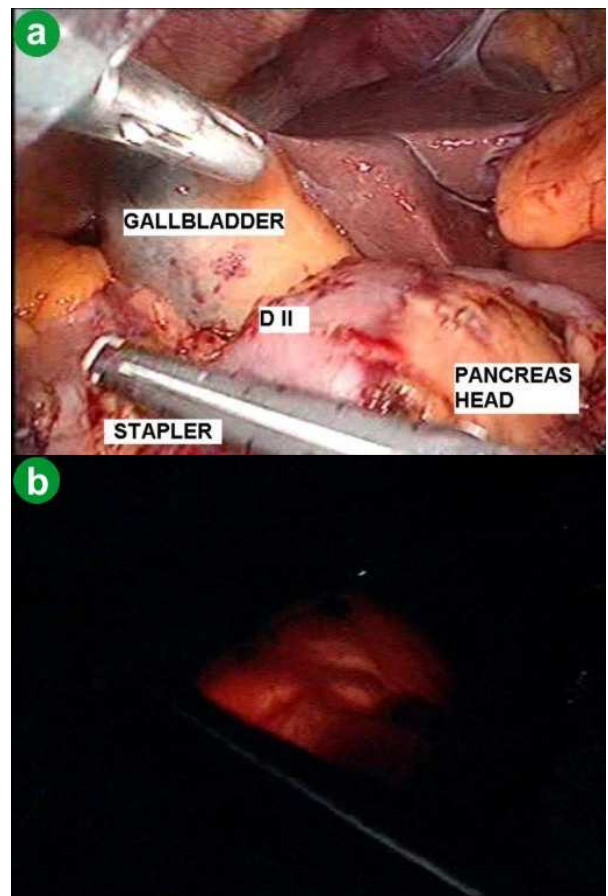


Figure 5. Sectioning of the duodenum infrapapillary under endoscopic control view. D II: second portion of the duodenum

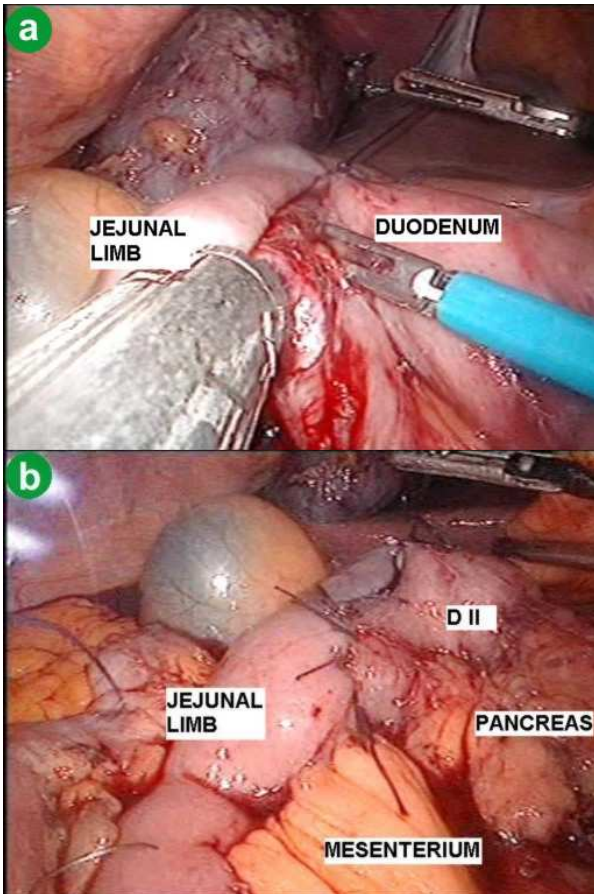


Figure 6. Stapled side-to-side duodenojejunostomy. D II: second portion of the duodenum

reconstructed in a transmesocolic side-to-side duodenojejunostomy (45 mm linear cutter and 2.5 mm stapler and the enterotomy was closed with interrupted 2-0 polyglactin sutures) (Figure 6). The specimen was removed through the umbilical trocar and protected in a bag. The operation lasted 227 minutes.

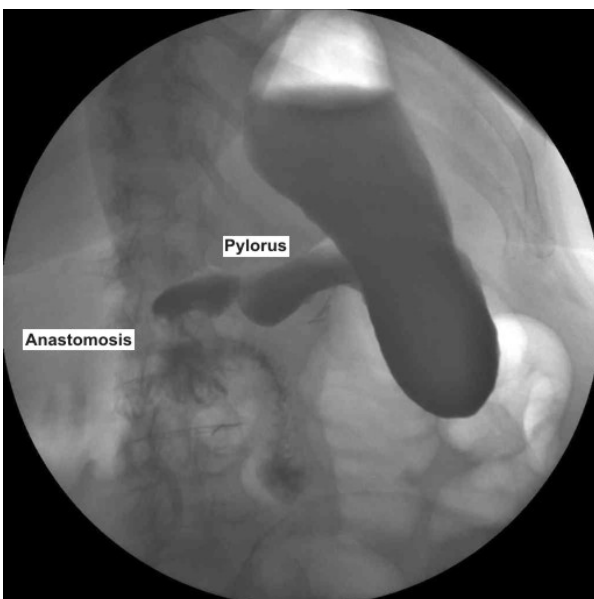


Figure 7. Postoperative swallow control.

The patient started oral intake on the 3rd postoperative day following a swallow control (Figure 7). Recovery was uneventful and she was discharged on the 7th postoperative day. Upper digestive endoscopy performed three months after surgery showed a normal anastomosis.

Final diagnosis was primary duodenal adenocarcinoma (moderate differentiation) over a villous adenoma. The size of the tumor was 75x55x19 mm (Figure 8). The depth of invasion was 3 mm near the serosa. Proximal (15 mm), distal and tangential resection margins were not affected. There was neither perineural nor microvascular invasion. No lymph nodes were harvested. One month after the surgical procedure, adjuvant chemotherapy was given (four cycles with oxaliplatin and capecitabine). After forty-five months of follow-up, there is no evidence of either local recurrence or metastatic disease on abdominal CT and upper digestive endoscopy.

DISCUSSION

Overall 5-year survival for primary adenocarcinoma of the duodenum is 23-31% [5, 6], rising to 51-60% [2, 4, 5, 6, 10] in resected patients. The reported experience from the Memorial Sloan-Kettering Cancer Center [5] showed that nodal metastases, regardless of their location, do not have an impact on survival. Only resectability and the presence of non-nodal metastases

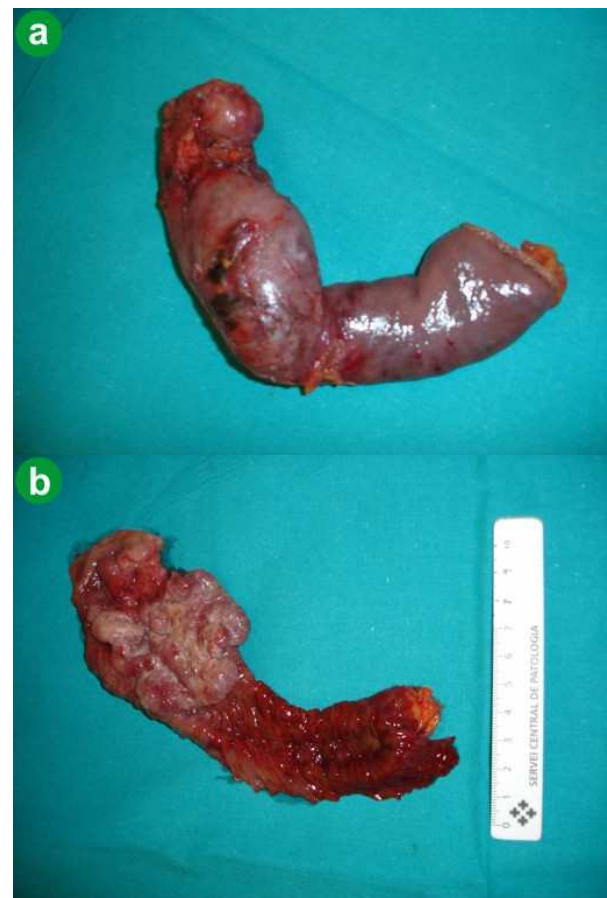


Figure 8. Resected duodenal specimen showing the size of the tumor and macroscopically free margins.

predict outcome. In this way, the Mayo Clinic experience [2] reports that lymph node metastasis, advanced tumor stage, and positive resection margins are associated with decreased survival, and hence recommends pursuing negative resection margins. These findings are supported by the majority of authors [3, 10]. When considering oncological benefits, segmental duodenal resection and wide local excision instead of a pancreaticoduodenectomy seem to be appropriate for selected patients, especially for tumors of the distal duodenum [6, 10]. A pancreaticoduodenectomy is an aggressive procedure well justified for the treatment of neoplasms of the head of the pancreas, periampullary area and duodenum, although it has considerable morbidity and mortality. For treatment of distal primary adenocarcinoma of the duodenum, a pancreaticoduodenectomy is associated with an increase in postoperative complications when compared to segmental duodenal resection even though they have equal outcomes [4, 6]. Primary adenocarcinoma of the duodenum usually extends to the pancreas. Direct extension of the tumor into the pancreas and involvement of pathological lymph nodes can now be preoperatively well documented by endoscopic ultrasonography, with subsequent consideration of segmental duodenal resection as an alternative treatment option.

The pancreas-sparing duodenectomy technique for the treatment of infra-ampullary duodenal pathologies was first described in 1996 [8] for tumors located in the 3rd and/or 4th portions of the duodenum. In this case, the difficulty of a successful pancreas-sparing duodenectomy was that the tumor was located infra-papillary, thus it was mandatory to perform an intra-operative duodenoscopy to preserve the papilla of Vater while maintaining disease-free margins when sectioning the duodenum. A laparoscopic pancreas-sparing duodenectomy has been described once in the literature, but only for the treatment of a benign peptic stricture of the 4th portion of a very distended duodenum [9]. This is the first time that this procedure has been described for the treatment of duodenal tumors and for lesions involving the 3rd portion of the duodenum. Obviously, not only adequate experience in pancreatic surgery but also expertise in laparoscopy is mandatory for carrying out this procedure. Due to the

difficulty involved in obtaining a large series of these rare tumors and since long term follow-up of this case is not yet available, we recommend this procedure as a less morbid option than a pancreaticoduodenectomy for the treatment of benign and pre-malignant infra-ampullary duodenal pathologies. It can also be a treatment option for patients suffering from duodenal gastrointestinal stromal tumors and for patients ruled out for a pancreaticoduodenectomy if the tumor is confined to the duodenal wall.

Disclosure statement No competing financial interests exist

References

1. Bal A, Joshi K, Vaiphei K, Wig JD. Primary duodenal neoplasms: a retrospective clinico-pathological analysis. *World J Gastroenterol* 2007; 13:1108-11. [PMID 17373748]
2. Bakaeen FG, Murr MM, Sarr MG, Thompson GB, Farnell MB, Nagorney DM, et al. What prognostic factors are important in duodenal adenocarcinoma? *Arch Surg* 2000; 135:635-41. [PMID 10843358]
3. Kaklamanos IG, Bathe OF, Franceschi D, Camarda C, Levi J, Livingstone AS. Extent of resection in the management of duodenal adenocarcinoma. *Am J Surg* 2000; 179:37-41. [PMID 10737576]
4. Sohn TA, Lillemoe KD, Cameron JL, Pitt HA, Kaufman HS, Hruban RH, Yeo CJ. Adenocarcinoma of the duodenum: factors influencing long term survival. *J Gastrointest Surg* 1998; 2:79-87. [PMID 9841972]
5. Rose DM, Hochwald SN, Klimstra DS, Brennan MF. Primary duodenal adenocarcinoma: a ten-year experience with 79 patients. *J Am Coll Surg* 1996; 183:89-96. [PMID 8696551]
6. Tocchi A, Mazzoni G, Puma F, Miccini M, Cassini D, Bettelli E, Tagliacozzo S. Adenocarcinoma of the third and fourth portions of the duodenum: results of surgical treatment. *Arch Surg* 2003; 138:80-5. [PMID 12511157]
7. Maher MM, Yeo CJ, Lillemoe KD, Roberts JR, Cameron JL. Pancreas-sparing duodenectomy for infra-ampullary duodenal pathology. *Am J Surg* 1996; 171:62-7. [PMID 8554153]
8. Tsiotos GG, Sarr MG. Pancreas-preserving total duodenectomy. *Dig Surg* 1998; 15:398-403. [PMID 9845621]
9. Ammori BJ. Laparoscopic pancreas-preserving distal duodenectomy for duodenal stricture related to nonsteroidal antiinflammatory drugs (NSAIDs). *Surg Endosc* 2002; 16:1362-33. [PMID 12072993]
10. Barnes G Jr, Romero L, Hess KR, Curley SA. Primary adenocarcinoma of the duodenum: management and survival in 67 patients. *Ann Surg Oncol* 1994; 1:73-8. [PMID 7834432]