

CASE REPORT

Middle-Preserving Pancreatectomy: An Interesting Procedure for Pancreas-Sparing Resection

Cosimo Sperti, Maria Laura Polizzi, Margherita Moro,
Valentina Beltrame, Sergio Pedrazzoli

Department of Medical and Surgical Sciences, University of Padua. Padua, Italy

ABSTRACT

Context Total pancreatectomy is the treatment of choice for multicentric diseases involving the head and the body-tail of the pancreas. Middle-preserving pancreatectomy is a recently reported alternative procedure when the pancreatic body is spared from disease. We report on the successful preservation of the pancreatic body in a patient harboring a multicentric intraductal papillary mucinous neoplasia (IPMN). **Case report** A multicentric IPMN was diagnosed in a 59-year-old man. A standard pylorus preserving pancreaticoduodenectomy was performed, followed by a spleen-preserving distal pancreatectomy. The splenic vessels were carefully preserved. The residual 5 cm of the pancreatic body were anastomosed to the jejunum after verifying that the resection line on both sides was negative at frozen section examination. The postoperative course was complicated by transient peritoneal bleeding managed with angiographic embolization of the splenic artery. A borderline mixed type IPMN of the head and chronic pancreatitis of the tail were found at pathological examination. Eleven months after surgery, the patient is well and disease free; glycemic control is achieved by diet. **Conclusion** A middle-preserving pancreatectomy can be performed safely for multicentric IPMNs involving the head and the body-tail of the gland. It can prevent problems with the glycemic control that usually follows total pancreatectomy.

INTRODUCTION

In recent years, parenchyma-sparing pancreatic resections (i.e., middle pancreatectomy, duodenum-preserving pancreatic head resection, spleen-preserving distal pancreatectomy) have been increasingly performed for isolated, benign, borderline or low-grade pancreatic malignancies not suitable for enucleation [1]. However, total pancreatectomy is still the treatment of choice for such diseases when the head and the body-tail of the gland are simultaneously involved. Problems with glycemic control and severe exocrine pancreatic insufficiency are obviously to be expected after a total pancreatectomy.

Intraductal papillary mucinous neoplasms (IPMNs) of the pancreas are multifocal in up to 64% of patients [2]. Choosing between total pancreatectomy and more limited resections may be difficult in clinical practice when faced with benign or borderline lesions of the

pancreas, and the balance between radical resection and postoperative quality of life has to be carefully considered [3]. When the lesion involves only the head and tail of the pancreas, the body of the gland may be spared by means of a middle-preserving pancreatectomy, preventing the consequences of the complete loss of the pancreatic parenchyma [4, 5, 6]. We describe the surgical technique and outcome in a patient who underwent a middle-preserving pancreatectomy.

CASE REPORT

In August 2005, a 59-year-old man underwent ultrasonography (US) and magnetic resonance cholangiopancreatography (MRCP). A multicystic mass, 2.5 cm in diameter, in the head of the pancreas was found incidentally. A branch-type IPMN was diagnosed and the patient was put on follow-up. A slight, progressive increase in tumor diameter was apparent on subsequent MRCP evaluation. In December 2008, the lesion measured 4.0 cm in diameter, with dilation of the main pancreatic duct, evidence of irregularity of the main pancreatic duct and a cystic lesion in the pancreatic tail (Figure 1). His physical examination was unremarkable, and routine laboratory tests were within normal range, including serum tumor markers CEA and CA 19-9. 18-fluorodeoxyglucose positron emission tomography with CT acquisition (PET/CT) showed no pathological uptake in the pancreas. Endoscopic ultrasonography showed a 3.5 cm cystic mass in the pancreatic head

Received January 28th, 2010 - Accepted March 11th, 2010

Key words Glucose Tolerance Test; Pancreas; Pancreatectomy; Pancreatic Neoplasms

Abbreviations PET/CT: 18-fluorodeoxyglucose positron emission tomography with CT acquisition

Correspondence Cosimo Sperti
Department of Medical and Surgical Sciences, University of Padua
Via Giustiniani 2, 35128 Padova, Italy
Phone: +39-049.821.8845; Fax +39-049.821.8821
E-mail: csperti@libero.it

URL <http://www.serena.unina.it/index.php/jop/article/view/3824/4266>

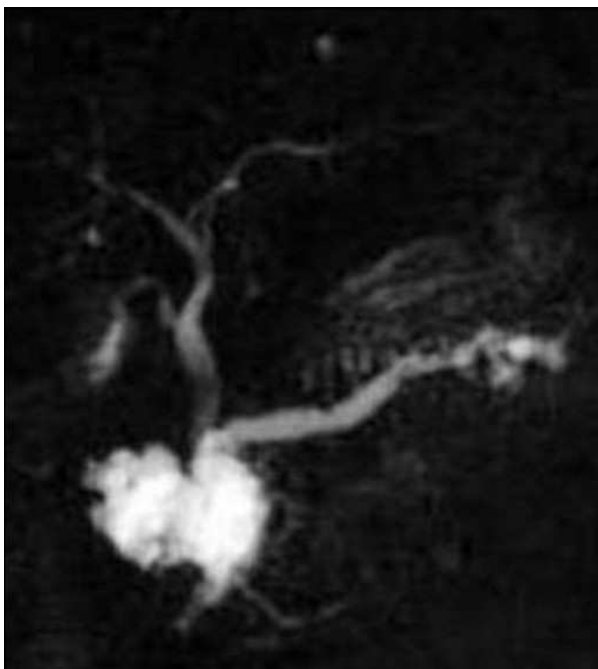


Figure 1. Magnetic resonance cholangiopancreatography showing a multicystic lesion in the pancreatic head, a slight dilation of the main pancreatic duct, and Wirsung's duct irregularity and cystic lesions in the tail of the pancreas.

with septa and mural nodules, communicating with a dilated main pancreatic duct. The body of the gland was normal, but a dilated main pancreatic duct and cystic lesions of secondary ducts were observed in the tail. With a diagnosis of mixed-type IPMN involving the head and tail of the pancreas, the patient underwent laparotomy.

After a midline incision, the peritoneal cavity was carefully explored and the pancreas was exposed. An intraoperative US confirmed the lesions in the head and tail of the pancreas while the body was free of disease. A standard pylorus-preserving pancreaticoduodenectomy [7] was performed followed by a spleen-preserving distal pancreatectomy with careful dissection of the splenic vessels. Both resection lines were negative at frozen section and the distal pancreatic stump was sutured. Blood supply and venous perfusion for the remaining gland were intraoperatively confirmed by normal bleeding from both cut surfaces of the pancreas. The remaining body of the pancreas, measuring about 5 cm in length, was anastomosed end-to-end to a Roux en-Y jejunal loop. A small catheter was left inside the main pancreatic duct, passing through the pancreaticojejunostomy. An end-to-end duodenojejunosotomy and an end-to-side hepaticojejunosotomy were also performed. Figure 2 shows the end result of the surgical procedure.

A preoperative oral glucose tolerance test and fecal elastase were within the normal range.

Histological examination of the surgical specimen confirmed a borderline, mixed-type IPMN in the head, and chronic pancreatitis in the tail of the pancreas.

The postoperative course was complicated by transient peritoneal bleeding and a suspected splenic hematoma

which was managed with blood transfusions and angiographic embolization of the splenic artery. Eleven months after surgery, the patient is well and disease-free. He is diabetic, treated only with diet, and his fecal elastase is less than 50 µg/g. He is taking pancreatic enzymes.

DISCUSSION

Multicentric diseases of the pancreas can be associated with several different conditions, including IPMN, and may afford a better choice of treatment. The involvement of two or more pancreatic regions by frankly malignant lesions generally warrants a total pancreatectomy. But while a total pancreatectomy is mandatory for malignancies, it seems to be overtreatment for benign or borderline conditions, especially in young, otherwise healthy, patients.

In our patient, surgical treatment was chosen after 3.5 years of follow-up on the basis of the increased risk of malignancy of a mixed-type IPMN with a lesion which had increased from 2.5 to 3.5-4 cm in the head of the pancreas in a patient who was a good surgical risk [8]. A duodenum-preserving pancreatic head resection was excluded due to the involvement of the intrapancreatic biliary tree and the duodenum. A total pancreatectomy was also excluded based on the normal appearance of the pancreatic body and on the negativity of PET/CT which excluded a malignant IPMN [9]. The choice of performing a spleen-preserving middle-preserving pancreatectomy was based on the hope of preventing possible brittle diabetes, and the related very poor quality of life which can follow a total pancreatectomy. A middle-preserving pancreatectomy can be criticized on the basis of the risk of recurrence of the IPMN in the residual pancreas. In the last decade, there has been great interest in organ-sparing pancreatic surgery for

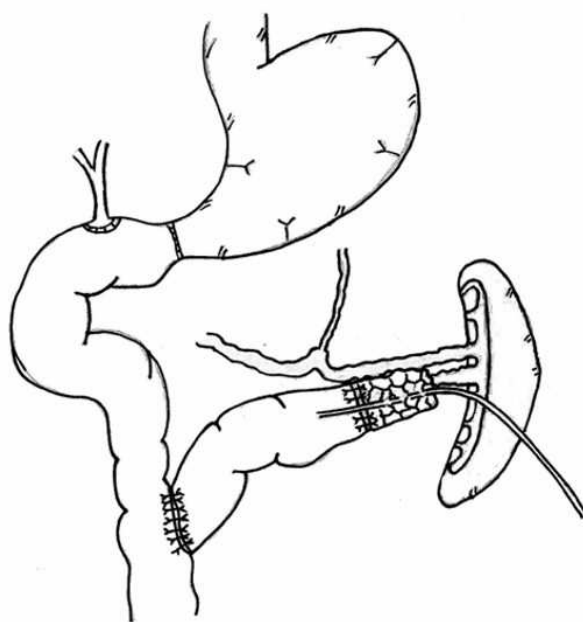


Figure 2. The end result of middle-preserving pancreatectomy with double jejunal loop reconstruction.

IPMNs involving isolated segments of the pancreas, with a view to preserving pancreatic function and achieving a better quality of life after surgery. Recurrent IPMN after subtotal duodenum-preserving pancreatic head resection was reported in only two out of 59 patients who underwent duodenum-preserving pancreatic head resection for IPMN [10]. Careful patient selection, and intraoperative frozen section of the surgical margins should be performed to prevent tumor relapse.

After a complicated postoperative course, the patient did well after discharge and, eleven months after surgery, there are no signs of IPMN relapse. His diabetes is still controlled by diet and exocrine insufficiency by pancreatic enzymes.

In the English language medical literature, we identified a total of 10 patients (our own included) who underwent middle-preserving pancreatectomies at four different institutions [4, 5, 6]. The results are summarized in Table 1.

Although pancreatic or ampullary cancers were resected in four of the ten patients [4, 5], we preferred to avoid a middle-preserving pancreatectomy in patients with malignant disease. Three patients experienced postoperative complications, involving two grade B pancreatic fistulas and peritoneal bleeding in one. None of the patients died. At the last follow-up, four patients had insulin-dependent diabetes easily controlled by low-dose insulin administration, and four had exocrine pancreatic insufficiency. All patients were alive without recurrent disease at the last follow-up (mean: 24.9 months; median: 16 months; range: 6-118 months).

In conclusion, a middle-preserving pancreatectomy is a recently introduced procedure to avoid total pancreatectomy in patients with multiple pancreatic diseases sparing only the body of the pancreas. The procedure is feasible and safe, with an acceptable complication rate. Exocrine and/or endocrine pancreatic sufficiency may be preserved in at least one

out of two patients; when it was not, the resulting pancreatic insufficiency proved much easier to treat than after total pancreatectomy. It has previously been shown that post-pancreatectomy glucose intolerance exhibits a linear relationship with the size of the pancreatic resection, both in animals [11] and in humans [12]. Dogs developed glucose intolerance after a 50% pancreatectomy and frank diabetes following resection of 87% of the gland [11]. In humans, there was usually little change in glycemic control unless more than 80% of the pancreas was resected in patients with a previously normal pancreas [12]. Therefore, post-pancreatectomy glycemic control may be related not only to the extent of the pancreatic resection, but also to the quality of the remaining pancreas. Moreover, a middle-preserving pancreatectomy preserves the glucagon-secreting alpha cells located in the pancreatic body; their loss is responsible for postoperative hypoglycemic episodes [12].

From the oncological point of view, a middle-preserving pancreatectomy appears to be an adequate surgical procedure for benign or borderline tumors, including IPMNs.

Acknowledgements We thank Miss Tania Lazzarin for her help in the preparation of the manuscript

Conflict of interest The authors have no potential conflict of interest

References

1. Aranha GV, Shoup M. Nonstandard pancreatic resections for unusual lesions. *Am J Surg* 2005; 189:223-8. [PMID 15720996]
2. Salvia R, Crippa S, Falconi M, Bassi C, Guarise A, Scarpa A, Pederzoli P. Branch-duct intraductal papillary mucinous neoplasms of the pancreas: to operate or not to operate? *Gut* 2007; 56:1086-90. [PMID 17127707]
3. Takada T, Amano H, Ammori BJ. A novel technique for multiple pancreatectomies: removal of uncinate process of the

Table 1. Middle-preserving pancreatectomy: review of patients reported in the English language medical literature.

Authors	No. of patients	Pathology	Morbidity	Mortality	Follow-up (months)	Diabetes	Malabsorption
Siassi 1999, [4]	1 ^a	Pancreatic cancer	0	0	Alive; no evidence of disease (12)	IDD	NR
Miura 2007, [5]	1 ^b	IPMN, pancreatic cancer	0	0	Alive; no evidence of disease (20)	No	No
	1 ^c	IPMN, ampullary carcinoma	0	0	Alive; no evidence of disease (10)	No	No
	1	IPMN, ampullary carcinoma	1	0	Alive; no evidence of disease (6)	IDD ^d	No
Partelli 2009, [6]	1	NF-PET-UB	1	0	Alive; no evidence of disease (118)	No	Yes
	1	NF-WDEC	0	0	Alive; no evidence of disease (22)	No	No
	1	IPMN	0	0	Alive; no evidence of disease (20)	IDD	Yes
	1	IPMN, chronic pancreatitis	0	0	Alive; no evidence of disease (18)	No	No
	1	Retention cyst, chronic pancreatitis	0	0	Alive; no evidence of disease (14)	IDD	Yes
Our patient	1	IPMN	1	0	Alive; no evidence of disease (11)	DM	Yes
Total	10	-	3	0	-	IDD: 4 DM: 1 No: 5	Yes: 4 No: 5 NR: 1

DM: diabetes mellitus; IDD: insulin dependent diabetes; IPMN: intraductal papillary mucinous neoplasm; NF-PET-UB: non-functioning endocrine tumor with uncertain behavior; NF-WDEC: non-functioning well-differentiated endocrine carcinoma; NR: not reported

^a distal pancreatectomy for adenocarcinoma followed by pylorus-preserving pancreaticoduodenectomy for adenocarcinoma

^b pancreaticoduodenectomy for IPMN followed by distal pancreatectomy for pancreatic cancer

^c distal pancreatectomy for IPMN followed by pylorus-preserving pancreaticoduodenectomy for ampullary carcinoma

^d Patient with diabetes preoperatively

pancreas combined with medial pancreatectomy. J Hepatobiliary Pancreat Surg 2000; 7:49-52. [PMID 10982591]

4. Siassi M, Klein P, Hohenberger W. Organ-preserving surgery for multicentric carcinoma of the pancreas. Eur J Surg Oncol 1999; 25:548-50. [PMID 10527608]

5. Miura F, Takada T, Amano H, Yoshida M, Toyota N, Wada K. Middle-preserving pancreatectomy. J Am Coll Surg 2007; 204:720-2. [PMID 17382235]

6. Partelli S, Boninsegna L, Salvia R, Bassi C, Pederzoli P, Falconi M. Middle-preserving pancreatectomy for multicentric body-sparing lesions of the pancreas. Am J Surg 2009; 198:e49-53. [PMID 19716880]

7. Pedrazzoli S, Beger HG, Obertop H, Andrén-Sandberg Å, Fernandez-Cruz L, Henne-Bruns D, et al. A surgical and pathological based classification of resective treatment of pancreatic cancer. Summary of an International Workshop on surgical procedures in pancreatic cancer. Dig Surg 1999; 16:337-45. [PMID 10449979]

8. Tanaka M, Chari S, Adsay V, Fernandez-del Castillo C, Falconi M, Shimizu M, et al. International consensus guidelines for

management of intraductal papillary mucinous neoplasms and mucinous cystic neoplasms of the pancreas. Pancreatology 2006; 6:17-32. [PMID 16327281]

9. Sperti C, Bissoli S, Pasquali C, Frison L, Liessi G, Chierichetti F, Pedrazzoli S. 18-fluorodeoxyglucose positron emission tomography enhances computed tomography diagnosis of malignant intraductal papillary mucinous neoplasms of the pancreas. Ann Surg 2007; 246:932-7. [PMID 18043094]

10. Beger HG, Gansauge F, Siech M, Schwarz M, Poch B. Duodenum-preserving total pancreatic head resection for cystic neoplastic lesions of the head of the pancreas. J Hepatobiliary Pancreat Surg 2008; 15:149-56. [PMID 18392707]

11. Sun AM, Coddling JA, Haist RE. A study of glucose tolerance and insulin response in partially depancreatized dogs. Diabetes 1974; 23:424-32. [PMID 4598091]

12. Slezak LA, Andersen DK. Pancreatic resection: effects on glucose metabolism. World J Surg 2001; 25:452-60. [PMID 11344398]