

LETTER

Postmortem Sampling of the Pancreas for Histological Examination: What Is the Optimum Cut-Off Time?

Rohan Chaminda Siriwardana¹, Kamel Ismile Deen¹, Janaki Hevawesenthi²

Departments of ¹Surgery and ²Pathology, Ragama Teaching Hospital, Ragama, Sri Lanka

Dear Sir:

The pancreas is a solid organ rich in digestive enzymes. Hence, autolytic changes set in early after biological death. Tomita *et al.*, analyzing postmortem samples from different organs at intervals of 1, 3, 5, 10, 15 and 24 hours, found that the pancreas showed the earliest changes at 1 hour after death [1]. The optimum time before which tissue samples should be obtained from the pancreas for postmortem histological studies has not been well established. This postmortem study analyzes the quality of histological specimens with respect to time.

A total of 32 pancreata were retrieved en block with the duodenum at different time intervals after death. The median environmental temperature during sampling time was 27°C (range 23-32°C). All the fresh cadavers were kept at environmental temperature until sampling. The most common cause of death was trauma (n=17; 53.1%), followed by cardiac events (n=6; 18.8%). The mean±SD age of cadavers was 51±5.7 years,

At post-mortem examination, the macroscopic consistency of the pancreas was noted. The specimens were sectioned at 5 mm intervals. The samples were immediately fixed in 10% formal saline. Following adequate fixation, representative samples were taken from the head, body and tail of the pancreas. Tissue samples were stained in hematoxylin and eosin after preparation. The slides were examined under the light microscope at magnifications of 4, 10 and 100, respectively by two independent pathologists. The microscopic features were divided into six categories.

These were the nature of the ductal epithelium, the periductal architecture, the perilobular architecture, the intralobular architecture, protein plugs, and fat necrosis. Depending on the quality of the histological/cytoarchitectural features, the slides were divided into three categories (excellent, when all cytoarchitectural features could be clearly described), moderate (when early autolytic changes interfered with reporting but where it was possible to comment on histology) and poor (when no comment was possible due to autolysis).

The median collection time was 7 hours (range 3-20 h). In 7 patients (21.9%), the architecture was distorted with poor histological details. All these were collected after 8 hours. Three specimens (9.4%) collected at 9 (2 patients) and 11 hours showed partial autolysis and were included under the moderate category. Excellent quality slides were obtained in 22 cases (68.8%); in particular, all the specimens retrieved 8 hours or earlier were of excellent quality (Figure 1).

It is apparent that the best time to acquire postmortem specimens from the pancreas for histological examination is up to eight hours after death. However, acceptable samples may be taken up to twelve hours.

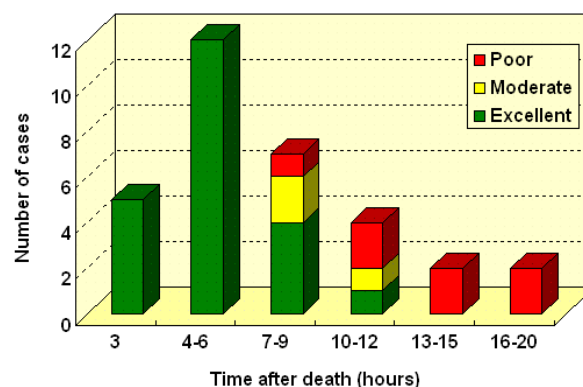


Figure 1. Quality of microscopic specimens according to time after death.

Received December 16th, 2009 - Accepted December 17th, 2009

Key words Pancreas /pathology; Postmortem Changes

Correspondence Rohan C Siriwardana

10/2 A Malwatta Road, Nugegoda, Sri Lanka

Phone: +94-0777.250.210; Fax: +94-0112.810.250

E-mail: rohansiriwardana@yahoo.com

URL <http://www.jop.unina.it/index.php/jop/article/view/3881/4323>

According to our knowledge, only one published study is available on the timing of pancreatic sampling [2].

Conflicts of interest The authors have no conflicts of interest

References

1. Tomita Y, Nihira M, Ohno Y, Sato S. Histological study of early postmortem changes in various organs: comparison of the paraffin embedding method and the epoxy resin embedding method. *Nihon Hoigaku Zasshi* 1999; 53:207-17. [PMID 10536439]
2. Nadzhani OL. About postmortem changes in the pancreas. *Arkh Patol* 1999; 61:16-9. [PMID 10664814]