

## HIGHLIGHT ARTICLE

---

# Novel Agents in Early Phase Clinical Studies on Refractory Pancreatic Cancer

Highlights from the "2012 ASCO Gastrointestinal Cancers Symposium". San Francisco, CA, USA. January 19-21, 2012

Alexios S Strimpakos<sup>1</sup>, Kostas N Syrigos<sup>1</sup>, Muhammad Wasif Saif<sup>2</sup>

<sup>1</sup>Oncology Unit, Third Department of Medicine, University of Athens, Sotiria General Hospital. Athens, Greece. <sup>2</sup>Columbia University College of Physicians and Surgeons and New York Presbyterian Hospital. New York, NY, USA

### Summary

The standard current treatment options in advanced pancreatic cancer have demonstrated minimal or modest only efficacy for the majority of patients. Unfortunately, the mortality and morbidity remain high crying out for better treatments and results. With the exception of erlotinib, which received approval by the Food and Drug Administration of the United States in 2005, no other novel agents have since been added in our treatment quiver. Therefore, the search for novel approaches continuous at the laboratory and clinical level. At the 2012 American Society of Clinical Oncology Gastrointestinal Symposium, results of some interesting early phases clinical studies were presented. First, in Abstract #198, toxicity and efficacy results from the phase I/II study of cixutumumab, an insulin growth factor-1 receptor (IGF-1R) antibody combined with the standard gemcitabine and erlotinib treatment were presented, but the outcomes suggest no real clinical benefit. Second, the early safety and clinical data from the novel monoclonal antibody (ensituximab) against the mucin epitope NPC-1C in pancreatic and colon cancer patients were presented (Abstract #233) and again no particular efficacy was observed. Finally, interesting results which definitely deserve further exploration were presented in Abstract #211, which tested the combination of ipilimumab, an antibody against the cytotoxic T-lymphocyte antigen 4 (CTLA-4), with a cell-based vaccine transfected with the granulocyte macrophage colony-stimulating factor (GM-CSF) gene in advanced refractory pancreatic cancer. Though, it seems we have not yet found the culprit and the solution of this devastating disease, a small step forward might have been achieved.

### What Did We Know Before 2012 ASCO Cancers Gastrointestinal Symposium?

The standard of care systemic treatment in advanced pancreatic cancer has long been the antimetabolite drug gemcitabine in combination either with the epidermal growth factor (EGF) inhibitor erlotinib or the oral fluoropyrimidine capecitabine or a platinum agent. More recently, another acceptable option is the non-gemcitabine regimen 5-fluorouracil plus folinic acid (leucovorin) plus irinotecan and oxaliplatin (FOLFIRINOX) which, though associated with increasing toxicity, appears promising in selected fit patients [1, 2, 3]. Over the last few years, there has

been presented preclinical evidence regarding new molecular targets and their treatments accordingly, requiring though further validation *in vivo* and in clinical trials [4]. For example, ensituximab, a chimeric antibody against the mucin NPC-1C epitope, which had showed recently antitumor activity against colorectal and pancreatic cancer cell lines, was evaluated in a phase I/IIA clinical study presented in this year's meeting as we demonstrate below.

### What Did We Learnt from 2012 ASCO Cancers Gastrointestinal Symposium?

In this review, some new data on biological agents are presented, few that allow us to be optimistic, and other less interesting that is unlikely to play important role.

#### Targeting IGF-1R with Cixutumumab (Abstract #198 [5])

In a multicenter phase I/phase II international study, the combination of the standard of care gemcitabine-erlotinib with or without cixutumumab was tested [5]. Cixutumumab in a novel inhibitor of the insulin growth factor-1 receptor (IGF-1R). The insulin growth factor-1 (IGF-1) pathway has been found upregulated in

**Key words** Adenocarcinoma; erlotinib; gemcitabine; Molecular Targeted Therapy; Pancreatic Neoplasms  
**Abbreviations** CTLA: cytotoxic T-lymphocyte antigen; GM-CSF: granulocyte macrophage colony-stimulating factor  
**Correspondence** Muhammad Wasif Saif  
Columbia University College of Physicians and Surgeons; New York Presbyterian Hospital; MHB, 6N-435; New York, NY 10032; USA  
Phone: +1-212.305.4954; Fax: +1-212.305.03035  
E-mail: mws2138@columbia.edu

**Table 1.** Clinical studies of novel agents in refractory pancreatic cancer.

Study	Treatment arms	Patient number	Outcomes	Comments
<b>SWOG-0727 Phase I/II Philip et al. United States</b>	Gemcitabine + erlotinib (Arm 1) <i>versus</i> Gemcitabine + erlotinib + cixutumumab (Arm 2)	Phase I: 10 Phase II: 124	Progression free survival: Arm 1: 7 months; Arm 2: 4 months	More females in Arm 2 Toxicities higher in Arm 2
<b>Phase Ib Le et al. United States</b>	Ipilimumab (Arm 1) <i>versus</i> Ipilimumab + vaccine (Arm 2)	Total 30 Arm 1: 15 Arm 2: 15	Best response (stable disease): Arm 1: 2 cases; Arm 2: 3  Median overall survival: Arm 1: 3.3 months; Arm 2: 5.5 months (P=0.12)  12-month overall survival: Arm 1: 7%; Arm 2: 27%	More previous treatment in Arm 2  Delayed responses were observed in 3 patients in Arm 2 High rates of immune related adverse events in both arms (more than 70%)

pancreatic cancer and suggested to play a role in the pathogenesis of this disease. The dual inhibition of EGF and IGF-1 aimed to cut off signal transduction of aberrant pathways. Table 1 demonstrates the design and outcomes of this study. The phase I part of this study (dose finding) showed that the optimal dose of cixutumumab was 6 mg/kg intravenously (i.v.) per week, combined with standard doses of gemcitabine (1,000 mg/m<sup>2</sup> i.v. on days 1, 8 and 15) and erlotinib (100 mg orally once a day). Toxicities from the addition of cixutumumab included higher rates of transaminitis and hematological toxicity (53% *versus* 39%) and a 27% rate of hyperglycemia.

Unfortunately, there was no clinical benefit with the progression free and overall survival been 4 and 7 months in both arms. In conclusion, this antibody does not seem to have a role in the management of advanced pancreatic cancer, at least in combination with gemcitabine and erlotinib.

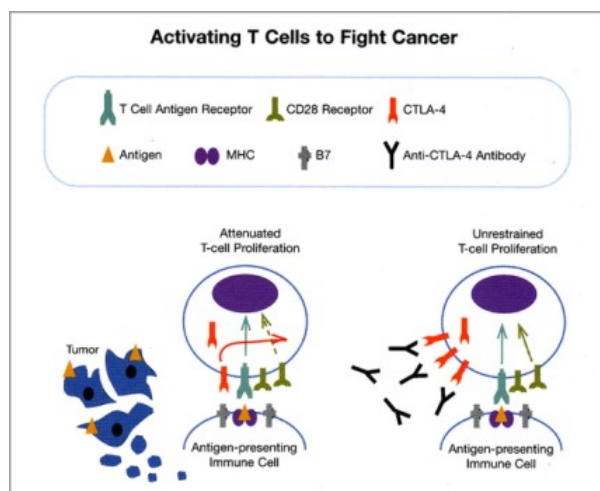
The Safety and Efficacy of Ensituximab. An Antimucin (MUC5AC) Antibody (Abstract #233 [6])

Ensituximab is a novel chimeric antibody against the epitope NPC-1C that is overexpressed in about 45-55% of pancreatic cancer and colorectal cell lines. It was

showed last year by Diaz *et al* that treatment of the above preclinical models with ensituximab resulted in antitumor activity *in vitro* and *in vivo* [7]. Based on these findings, the same team studied this agent in a phase I/IIA dose finding and early efficacy study (Abstract #233 [6]). Patients with advanced refractory pancreatic cancer or colorectal cancer were recruited and pharmacokinetics, safety and tolerability data were collected in the phase I dose escalation study, along with evaluation of the immunological response to the antibody at each dose level. The objectives of the phase IIA part of the study were evaluation of clinical response and the immune responses to the antibody. Fifteen patients (10 colorectal and 5 pancreatic) were recruited at three dose cohorts (1, 1.5 and 2 mg/kg i.v. ensituximab every two weeks). Some mild to moderate hemolysis was observed at the 2 mg/kg level, but no toxicity at all at the 1.5 mg/kg dose level, which is considered the optimal for this agent. As far as efficacy is concerned, one out of the five patients, evaluated with imaging (a patient with colorectal cancer), has showed so far disease stability after two months on treatment. There were no human antibodies to monoclonal antibodies (HAMA) in the evaluable patients. More data on pharmacokinetics and clinical efficacy are awaited. Regarding patients with pancreatic cancer, only one demonstrated disease stability and that happened only at the 2 mg/kg level.

First in Human Study of Ipilimumab in Pancreatic Cancer (Abstract #211 [8])

CTLA-4 is an antigen found on T-lymphocytes and its presence is associated with suppressed immune response to a disease. Thus, blocking its activity may be of value in cancer treatment (Figure 1). The role of ipilimumab, an anti-CTLA-4 antibody in the treatment of solid tumors has been highlighted after the positive results it showed in advanced melanoma, where it has been granted approval in the first line treatment at a dose of 10 mg/kg. Previous studies had showed that low doses of ipilimumab (3 mg/kg) were rather ineffective in pancreatic adenocarcinoma, but some delay of progression was noted in one patient [9]. Preclinical data in pancreatic cancer models had suggested that ipilimumab can act synergistically when combined with a vaccine based on tumor cells



**Figure 1.** The effect of CTLA-4 and its inhibition (adapted from the website of University of California San Francisco (UCSF) <http://www.ucsf.edu/news/2011/05/9803/ucsf-scientists-play-key-role-success-yervoy-new-cancer-drug>).

transfected with the granulocyte macrophage colony-stimulating factor (GM-CSF) gene, which acted as an immune booster. This hypothesis led Le *et al* to conduct a phase I study that tested ipilimumab at a dose of 10 mg/kg alone (arm 1) or with the vaccine (arm 2) (Abstract #211 [8]). Thirty patients with advanced pretreated pancreatic cancer were randomized (1:1) between the two arms and treated every 3 weeks for 4 cycles. Patients with disease stability or improvement were entitled for maintenance treatment every 12 weeks. Both arms showed similar rate of grade 3-4 toxicities (20%). Immune related adverse events and rash were less frequent in arm 1 (73% vs. 80 % and 53 vs. 73%, accordingly) than arm 2. Efficacy results are shown in Table 1. Interestingly, few patients on arm 2 showed delayed disease stabilization (one started on week 16 after treatment initiation, one after 22 weeks and one lasting for 64 weeks). The authors concluded that immunotherapy might improve efficacy of those selected patients whose life expectancy seems longer.

## Discussion

The management of advanced pancreatic cancer is always a challenge for the clinical doctors and a difficult situation for patients and families who have to come to terms with its poor prognosis. The failure of an actually effective treatment for the present time is likely due to the complexity of the pathogenesis of pancreatic cancer, the numerous molecular alterations that take place and that evolve over time, as well as the possible mechanisms of drug resistance. Therefore, for a long time there has been continuous effort to combine drugs (cytotoxics, biological, vaccines) that act at various levels and with various mechanisms, aiming to achieve the best response with the least adverse reactions. In this review, we learnt that addition of the IGF-1 receptor antibody cixutumumab to the standard treatment gemcitabine and erlotinib did not benefit patients with advanced pancreatic cancer, though generally well tolerable. It remains though the question whether there might be a subpopulation that could get any advantage from this approach, or how this antibody works with other drugs used in pancreatic cancer, but this needs to be explored in other studies.

Similarly, negative preliminary results were observed from the trial of ensituximab, the monoclonal antibody against MUC5AC antigen, in pancreatic and colorectal cancer patients. Though the number of patients enrolled was very small, it seems that there is no role of this agent in pancreatic cancer treatment, at least on

its own. Whether there is any benefit or synergism from combination with other biological or chemotherapy agents needs to be studied.

More promising, but still modestly satisfactory, is the effect from the combination of ipilimumab with the GM-CSF vaccine. This approach seems to benefit some patients with advanced pancreatic cancer for a good period of time, offering survival benefit without unacceptable toxicities. There is no doubt we need more translational studies to identify the predictive and prognostic biomarkers correlated with this treatment. This is the only way we can apply a truly personalized medicine in pancreatic cancer patients, as is the case in other solid tumors.

Finally, it is obvious and we have to cry it out that only more research, clinical and translational, and encouragement of patients to participate in the conducted studies can only move things forward.

---

**Conflict of interest** The authors have no potential conflicts of interest

---

1. Sultana A, Smith CT, Cunningham D, Starling N, Neoptolemos JP, Ghaneh P. Meta-Analyses of Chemotherapy for Locally Advanced and Metastatic Pancreatic Cancer. *Journal of Clinical Oncology* 2007 Jun 20,25(18), 2607-2615.
2. Strimpakos A, Saif MW, Syrigos KN. Pancreatic cancer: from molecular pathogenesis to targeted therapy. *Cancer Metastasis Rev* 2008 Sep,27(3), 495-522.
3. Conroy T, Desseigne F, Ychou M, et al. FOLFIRINOX versus gemcitabine for metastatic pancreatic cancer. *N Engl J Med* 2011 May 12,364(19), 1817-1825.
4. Strimpakos AS, Syrigos KN, Saif MW. The molecular targets for the diagnosis and treatment of pancreatic cancer. *Gut Liver* 2010 Dec,4(4), 433-449.
5. Philip PA, Goldman BH, Ramanathan RK, et al. Phase I randomized phase II trial of gemcitabine, erlotinib, and cixutumumab versus gemcitabine plus erlotinib as first-line treatment in patients with metastatic pancreatic cancer (SWOG-0727). *J Clin Oncol (Meeting Abstracts)* 2012 Jan 30,30(4\_suppl), 198.
6. Morse M, Diaz LA, Azad NS, et al. A phase I/IIA safety study of NPC-1C: A novel, therapeutic antibody to treat pancreas and colorectal cancers. *J Clin Oncol (Meeting Abstracts)* 2012 Jan 30,30(4\_suppl), 233.
7. Diaz LA, Azad NS, Laheru D, et al. NPC-1C: A novel, therapeutic antibody to treat pancreas and colorectal cancers. *ASCO Meeting Abstracts* 2011 Feb 3,29(4\_suppl), 235.
8. Le DT, Lutz E, Huang L, et al. Phase Ib study of ipilimumab alone or in combination with allogeneic pancreatic tumor cells transfected with a GM-CSF gene (vaccine) in pancreatic cancer. *J Clin Oncol (Meeting Abstracts)* 2012 Jan 30,30(4\_suppl), 211.
9. Royal RE, Levy C, Turner K, et al. Phase 2 trial of single agent Ipilimumab (anti-CTLA-4) for locally advanced or metastatic pancreatic adenocarcinoma. *J Immunother* 2010 Oct,33(8), 828-833.